


PRESENTING CLINICAL SIGNS

DATE History: New grade 3/6 murmur with jugular pulse. Experiencing lethargy. BNP 1586.

ECHOCARDIOGRAPHIC FINDINGS

2D, M-mode, and Doppler study.

PERFORMED BY:

Dr. Sarah Barthelemy

INTERPRETED BY

Keith Blass, DVM,
MS, DACVIM
(Cardiology)

There is mild left atrial dilation. The mitral valve leaflets are mildly thickened, and a mild to moderate jet of eccentric mitral regurgitation is present. Left ventricular dimensions are normal. Left ventricular systolic function is hyperdynamic. The aorta and aortic valve are normal. Right atrial and right ventricular dimensions are normal. The tricuspid valve leaflets are mildly thickened, and a mild jet of tricuspid regurgitation is present. TR velocity is consistent with the presence of moderate pulmonary hypertension (PG 64.6 mmHg). The pulmonary artery and pulmonic valve appear normal, though trace pulmonic insufficiency is present. No shunting lesions are visualized. No heartworms are visualized. There is an ~7.39 cm x 6.88 cm homogeneous mass at the heart base best seen adjacent to the aortic root and left atrium. No pericardial effusion is seen.

PATIENT

Merlin Chaparro

LA - 41.5 mm
LVIDd - 32.7 mm
LVIDs - 16.2 mm
FS - 50.5%
RA - 27.9 mm
LVOT - 1.22 m/s
RVOT - 0.92 m/s
TR - 4.02 m/s

SPECIES

Canine

ASSESSMENT/RECOMMENDATIONS
BREED

Beagle

Degenerative mitral and tricuspid valve disease
Pulmonary hypertension
Heart base mass

SEX
MN
AGE

10 y

This examination demonstrates regurgitation of blood across Merlin's mitral and tricuspid valves resulting from degenerative valve disease. Merlin's tricuspid valve disease is mild, and appears to be well-compensated at this time. His mitral valve disease is a bit more advanced, as Merlin has mild to moderate mitral regurgitation present, with mild secondary dilation of his left atrium, though his left ventricular dimensions are normal, and his left ventricular systolic function is well-preserved. As only mild left atrial dilation is present, Merlin's mitral valve disease appears to be well-compensated, and his current risk for the development of left-sided congestive heart failure appears to be relatively low.

WEIGHT

13.2 kg

Merlin's tricuspid regurgitation velocity is consistent with the presence of moderate pulmonary hypertension. It's possible that Merlin's pulmonary hypertension could be the cause of his lethargy, and the disease also puts him at risk for the development of exercise intolerance and syncope.

HOSPITAL NAME

Brittania Kingsland
VC

Also seen in this exam is a large mass at Merlin's heart base. While a biopsy would be required to determine the etiology of the mass, its appearance and location are suggestive of the presence of a chemodectoma. While metastasis is possible with this tumor type, it is uncommon, and dogs are at higher risk for the development of clinical signs secondary to the mass bleeding into the pericardial space and/or obstructing blood flow in a cardiac chamber or great vessel. Neither of these appears to have occurred so far, therefore, I suspect that Merlin's mass is an incidental finding right now, however, I can't rule out a paraneoplastic syndrome as a possible contributor to his lethargy.

REFERRING VET

Dr. Radcliffe



DATE Recommended therapy for Merlin's valvular diseases is pimobendan (5 mg am, 2.5 mg pm), while recommended therapy for his pulmonary hypertension is sildenafil (10 mg TID).

12/28/22 Thoracic radiographs and an abdominal ultrasound may be warranted to evaluate for metastatic disease. Consultation with an oncologist may be warranted to determine whether stereotactic radiation and/or therapy with Palladia or another chemotherapeutic agent may be beneficial.

PERFORMED BY: A recheck echocardiogram is recommended in 3-4 months, sooner if clinical signs compatible with cardiac tamponade (ex. severe lethargy, weakness, collapse, vomiting, labored breathing, abdominal distension) develop.
Dr. Sarah Barthelemy

INTERPRETED BY
Keith Blass, DVM, MS, DACVIM (Cardiology)

PATIENT
Merlin Chaparro

SPECIES
Canine

BREED
Beagle

SEX
MN

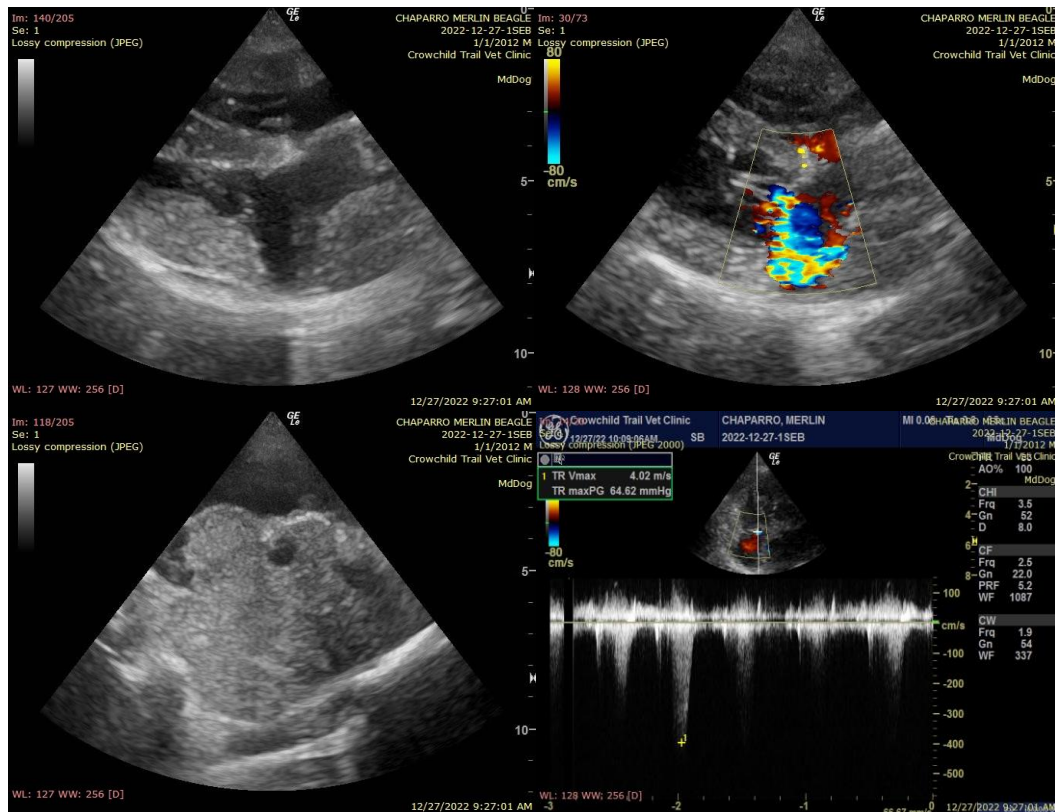
AGE The information and recommendations provided are based on the images presented by the referring veterinarian. No evaluation can be communicated regarding pathology that was not visible in the image/video clips provided.
10 y

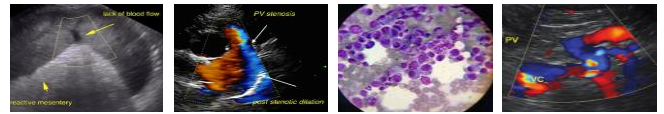
WEIGHT Thank you for this referral. If the clinical or image interpretation does not parallel your findings or if I can be of any further assistance please contact me.

13.2 kg

HOSPITAL NAME Keith Blass, DVM, MS, DACVIM (Cardiology)
KeithBlass@gmail.com
631-804-5754
Brittania Kingsland VC

REFERRING VET
Dr. Radcliffe





DATE

12/28/22

PERFORMED BY:

Dr. Sarah Barthelemy

INTERPRETED BY

Keith Blass, DVM,
MS, DACVIM
(Cardiology)

PATIENT

Merlin Chaparro

SPECIES

Canine

BREED

Beagle

SEX

MN

AGE

10 y

WEIGHT

13.2 kg

HOSPITAL NAME

Brittania Kingsland
VC

REFERRING VET

Dr. Radcliffe